

Morphology of Auditory Canal of Echidna (*Tachyglossus aculeatus*)

A. S. Saber¹ and A. Hassanin²

1 Department of Anatomy and Embryology, Faculty of Veterinary Medicine, University of Sadat City, Sadat City, Egypt & Discipline of Anatomy and Pathology, School of Veterinary and Biomedical Sciences, James Cook University, Townsville, Australia.

2 Department of Cytology and Histology, Faculty of Veterinary Medicine, University of Sadat City, Sadat City, Egypt.

With 9 figures

Received December 2013, accepted for publication March 2014

Abstract

The echidna is a monotreme a mammal that lay eggs and produces milk to nourish its young after hatching. Three short-beaked echidnas were used to study the morphology of their auditory canal. Three echidnas were dissected, two of them were x-rayed and samples for histological examination were taken from them before dissection.

The echidna possesses neither an apparent ear pinna nor a tympanic bulla. The auditory canal begins at the bottom of the auditory groove, which is vertically situated and hidden between the spikes of the head. It is hyaline cartilage in nature, and extends from the bottom of the auditory groove, running cranially; then after turning caudomedially. It ends at the slit-like external auditory opening of the skull. The epidermal layer of skin that lines the auditory

canal is keratinized stratified squamous epithelium. The deep dermal layer is formed of dense connective tissue of collagen and elastic fibers with hair follicles and a few associated sebaceous and ceruminous glands. The results were discussed in the light of the ear evolution from reptiles to the early mammals (monotremes) and supported by 9 images.

Introduction

There are only three types of monotreme living on the planet today: the short-beaked echidna, the long-beaked echidna and the platypus. They are mammals, have fur and produce milk to nourish their young, but are not quite like their fellow mammals, the marsupials and the placental mammals. The platypus and echidna lay eggs (oviparity), so their young are hatched, not born

alive (Augee et al., 2006).

The long-beaked echidna is found in New Guinea. The four subspecies of short-beaked echidna are found in Australia and both short and long-beaked types are found in New Guinea. The short-beaked echidna is classed as a myrmecophage (ant and termite specialist); however, they also eat larvae of other invertebrates such as the Scarab beetle, as well as other adult beetles and earthworms. These animals are protected in Australia and New Zealand. These animals were classified and their general anatomical characters were described in the old works of Mivart (1866), which was reproduced in 2008, and Beddard (1902), which was reproduced in 1958.

The published works on the monotremes and marsupials auditory system are very meager. Aitken and Johnstone (1972) described the middle-ear structure and function in the echidna. Chen and Anderson (1984) described the structure of the echidna's cochlear fine structure using the SEM. Jorgensen and Locket (1995) reported on the inner ear (vestibular sensory organs) structure of the echidna. The auditory function of the echidna was measured using different methods by Mills and Shepherd (2001), while the ear region physiology was stud-

ied in the marsupial sabre-tooth by Turnbull and Segell (1984). Another physiological approach to the hearing, vocalization and external ear of another marsupial, the Northern Quoll, was carried out by Aitken et al. (1994). Morphological description of the echidna's auditory canal is missing in the available literature; hence the goal of this study is to fill this gap concerning this region of the echidna morphology.

Keywords: short-beaked echidna (*Tachyglossus aculeatus*), monotremes, auditory canal, anatomy, histology.

Material and Methods

Three echidnas that had died from car accidents were delivered during the year 2013 to the Discipline of Anatomy and Pathology, School of Veterinary and Biological Sciences, James Cook University, Townsville, Australia. After the post mortem procedure on the first echidna, a piece of the auditory canal was taken and processed with routine histological methods, sectioned at 4 μm , stained with hematoxylin and eosin (H&E) and the Verhoeff stain for elastin tissue (Humason, 1972). The sections were photographed with a Samsung Camera. The other two echidnas (about 4,150 kg weight) were x-rayed (53 kV and 5 mAs) before dissection to describe the course and connection of the audi-

tory tube to the skull. One specimen was boiled and cleaned to get the skeleton using the maceration technique for skeleton preparation described by Simoens et al., (1994). Photographs were taken by a Samsung digital camera WB 700. *Nomina Anatomica Veterinaria* (2005) was utilized for denominating the anatomical terms in the study.

Results

The echidna possesses no apparent ear pinna. It seems that the funnel-like cartilaginous part of the ear pinna is dipped or embedded in the head musculature, leaving the external ear opening as a slit-like auditory groove. This groove is about 2 cm deep and 3 cm long, vertically situated and hidden between the spikes of the head region. This slit-like groove is encircled by a plate of cartilage under the lining skin of this groove. At the bottom of this groove, the auditory canal opening is situated (fig 1, 2). The auditory canal looks like a cartilaginous trachea, measuring about 6.5 cm long and 0.5 cm in diameter. It starts at the bottom of the auditory groove, directed cranio-ventrally for about 4.5 cm, then after inclines caudomedially to end at the slit-like external auditory opening of the skull (fig 3). This opening is about 5 mm long

and is margined by the sternomas-toid and cleidomastoid muscles (figs 4, 5). A tympanic bulla was not detected in echidna. From the beginning until ending at the skull, the cartilaginous tube lumen is studded with fine hairs.

Histological examination of the auditory canals revealed that it consisted of plates of hyaline cartilage covered by thin skin (fig 6). The chondrocytes were large, ovoid and polygonal, lying in lacunae and nearly filling them. The epidermal layer of skin was keratinized stratified squamous epithelium, while the dermal papillae were very short or nearly absent (fig 7). The deep dermal layer was formed of dense connective tissue of collagen and elastic fibers with hair follicles of different sizes and a few associated sebaceous and ceruminous glands (modified apocrine sweat glands) known to secrete the ear-wax (figs. 6-9).

Discussion

Because of the scanty information on the auditory organs morphology in monotremes, some of the results obtained were discussed in relation to what is known in some higher mam-mals, as well as reptiles and birds.

The only related description of the

external ear of echidna was given by Augee et al., (2006). They mentioned that the ear opening is not readily visible, because spines usually obscure it, but it is quite a large vertical slit. They added that the external ear (the pinna) is unlike that of other mammals and is formed by a large cartilaginous funnel that is largely buried in a superficial muscle. These observations support the findings of this study.

Hedgehogs (mammalian insectivores with hairy or spiny skin and resembles in appearance the echidna) have a fairly long snout, covered with whisker-like hairs, small bright brown/black eyes that protrude slightly and, contrary to echidnas, small ears about 1 cm (just under half inch) high³.

The present study demonstrated that the auditory canal is cartilaginous in nature and has the same caliber along its length; and that it ends rostral to the sternomastoid and cleidomastoid muscles. Mivart (1866) mentioned that the former muscle arises in close connection with its fellow of the opposite side, from the middle of the outer surface of the manubrium and inserts by a strong tendon in the region of the skull above and in front of the insertion of the Trachelo-mastoid m. The same muscle arrangement around the ear opening was described in the platy-

pus (another monotreme) by Diago et al. (2008) and Howett (1937).

Similar to that of other species, the auditory canal of the echidna is coated by thin skin, with an underlying dermis of fibroelastic tissue and a reinforcement of hyaline cartilage.

The presence of hair-rich skin lining the ear canal of the echidna resembles that described in many animal species as in sheep (Soares and Lavinsky, 2011) and dog (Heine, 2004). In the ox, Wilkie (1936) mentioned that the external ear possess at the mouth of the external bony meatus a roughened outline of four or more large points and a nearly circular opening of from 5-6 mm; the meatus widens out towards the drum, where it reaches a diameter of 10-12 mm. He also mentioned that the dermal papillae are shorter, with a tendency to blunt, almost club-shaped extremities in many cases. On the contrary, in the horse the papillae are long and slender, and narrowing towards the point, which in many cases shows a bifurcation. The dermal papillae of the echidna of the present study were very short or even absent.

The ceruminous glands in the echidna were numerous, showing apocrine secretions. Wilkie (1936) mentioned that the ceruminous glands in the ox are very large and

numerous, assume a globular shape, and follow one another so closely as to form an almost continuous ring around the meatus; in the horse these glands are much smaller in size, more isolated, and, although generally globular in shape, certain among them assume a more or less ovoid form.

In the present study the cartilaginous support of the auditory canal was hyaline cartilage, however it is elastic in nature in the rabbit (Takagi et al., 1983), dog (Heine, 2004) and human (Michaels, 1987 and Bull, 2002).

Monotremes have many features common to other mammals but also features common to early mammals and birds and reptiles (Milles and Shepherd (2001). Concerning the ear, in some reptiles (many lizards) the external ear is either absent or greatly reduced as in geckos and monitors ². The External ear is absent in the echidna as in these reptiles.

A monotreme's middle ear is typically mammalian, consisting of 3 bones with the same functions as in other extant mammals (Griffiths, 1968; Aitkin and Jonstone, 1972; Gates et. al.1974; Fleischer, 1978). Aitken and Johnstone (1972) added that, in the echidna, the malleus is large with a processus gracilus, the incus

is ankylosed to the malleus and the stapes is columelliform. On the other hand, amphibians have a single bone in the middle ear called "columella" which connects the tympanum to the inner ear ² (Gish, 1981).

Gish (1981) claimed that evolutionists maintain that the stapes corresponds to the columella and that the quadrate and articular bones of the reptiles somehow moved into the ear to become, respectively, the incus and malleus bones of the mammalian ear (as found in the echidna by Aitken and Johnstone, 1972). Also, that the development of the tympanic membrane gave the amniotes a middle ear in addition to their inner ear structures before they only had an inner ear (Manley, 2000).

The inner ear of the monotremes (echidna, platypus) is not typically mammalian but similar to that of birds and reptiles. The echidnas have more sensory organs than do other mammals, including a lagenar macula, a sense organ found in all non-mammalian vertebrates.

This macula consists of a narrow sensory strip at the end of the cochlea. The sensory epithelia are very large relative to the size of the animals. The utricular macula contains more sensory cells than found in any other amniote so far examined

(Jørgensen and Locket, 1995). In addition, Chen and Anderson (1984) mentioned that, unlike typical mammalian cochlea, the echidna possesses a less coiled cochlea with four rows of inner hair cells and 6-9 rows of outer hair cells, and that the arrangements of the stereocilia of the outer hair cells are not uniform throughout the length of the basilar membrane. Moreover, the possession of a lagena and also the presence of some stereocilia in a dense, bushy arrangement proximal to the oval window is characteristic of birds and reptiles.

In conclusion, the presence of the auditory tube representing the second part of the external ear of mammals, along with the absence of an apparent first part (i.e. an ear pinna) may be considered as a supporting proof of the peculiar position of the monotrematous echidna in the spectrum between reptiles, amphibians and birds on one side and the mammals on the other side.

Acknowledgment

We want to express our cordial thanks to Mrs. Kerry Johns, the Anatomy technician in the Discipline of Anatomy and Pathology, School of Veterinary and Biomedical Sciences, JCU for preparing the echidna skulls, and to Mr.

Chris Wright for preparing the histology slides used in this study.

References

Aitkin, L.M. and Johnstone, B.M. (1972): Middle-ear function in a monotreme: The echidna (*Tachyglossus aculeatus*). *Journal of Experimental Zoology*, Vol 180, Issue 2: 245-250.

Aitkin, L.M., Nelson, J.E. and Shepherd, R.K. (1994): Hearing, vocalization and the external ear of a marsupial, the northern quoll, *Dasyurus hallucatus*. *J Comp Neurol*. 349(3): 377-88.

Augee, M.; Gooden, B. and Musser, A. (2006): Echidna, Extraordinary egg-laying mammal. Australian National History Series. CSIRO publishing.

Beddard, F. (1958): Mammalia, Vol. X. a reprint edition from 1902, by Macmillan & Co., Limited

Bull, PD (2002): The ear: Some applied anatomy. In: Diseases of the ear, nose and throat. 9th ed. 1 - 4.

Chen, C.S. and Anderson, L.M. (1985): The inner ear of the echidna – an SEM study. *Experientia* 41, Birk-haeuser Verlag, CH-4010 Basel/ Switzerland.

Cole, L. (2010): Anatomy and phys-

iology of the canine ear. *Vet. Dermatol.* 21(2): 221-231.

Fleischer, G. (1978): Evolutionary principals of the mammalian middle ear. *Adv. Anat. Embryol.. Cell Biol.* 55: 1-67.

Gates, G.R.; Sauders, J.C. and Bock, G.R. (1974): Peripheral auditory function in the platypus, *Ornithorhynchus anatinus* . *J. Acoust. Soc. Am.* 56: 152-156

Gish, D. (1981): The mammalian-like reptiles.(Acts & Facts) 10 (12) . <http://www.icr.org/article/184/> (retrieved 28/10/2013).

Jorgensen, J.M. and Locket, N.A. (1995): The inner ear of the echidna *Tachyglossus aculeatus*: The vestibular Sensory Organs. *Proc. R. Soc. Lond. B*, vol. 260 no. 1358, 183-189.

Heine, PA. (2004): Anatomy of the ear. *Veterinary Clinics of North America-Small Animal Practice.* 34: 379-395.

Humason, G.L. (1972): *Animal Tissue Techniques.* 3rd ed. W.H. Freeman and Company

Manely, G.A. (2000): Cochlear Mechanisms from a Phylogenetic Viewpoint. *Proceedings of the National Academy of Sciences*, <http://www.pnas.org/content/97/2>

2/11736.full.pdf

Michaels, L. (1987): The normal ear. In: *Ear, Nose and Throat Histopathology.* London: Springer-Verlag. 11 - 23.

Mills, D.M. and Shepherd, R.K. (2001): Distortion product otoacoustic emission and auditory brainstem responses in the echidna (*Tachyglossus aculeatus*). *JARO* 02: 130-146.

Mivart, G. (1866): On some points in the anatomy of *Echidna hystrix*. Article read in February 1st 1866 and first published online: 22 July 2008.

Simoens, R., Poles, R. and Lauwers, H. (1994): Morphometric analysis of foramen magnum in Pekingese dogs. *American Journal of Veterinary Research*, 55: 33-39.

Soares, H.B and Lavinsky, L. (2011): Histology of sheep temporal bone. *Braz. j. Oto-rhinolaryngol. (Impr.)* vol. 77 no.3:

Takagi M, Parmley RT, Denys FR, Kageyama M. and Yagasaki H. (1983). Ultrastructural distribution of sulfated complex carbohydrates in elastic cartilage of the young rabbit. *Anat Rec.* 207(4): 547-56.

Turnbull W. D., Segall W. (1984): The ear region of the marsupial sabertooth, *Thylacosmilus*: influence of the sabertooth lifestyle upon it, and convergence with placental sabertooths. *J. Morphol. Embryol.* 181, 239–270.

Wilkie, H.C. (1936): The auditory organ of the ox (*Bos taurus*). Proceedings of the Zoological Society of London, Vol 106, Issue 4: 985-

1009.

Internet sites

1. <http://www.wildcare.org.au/Pages/Echidnas.html> (Retrieved 22/11/2013).
2. http://en.wikivet.net/Lizard_ear (retrieved 21/3/2014)
3. <http://www.wildlifeonline.me.uk/he-dgehogs.html#hearing> (retrieved 14/3/2014)

Corresponding Author:
Prof. Dr. Ashraf Sobhy Saber
E-mail: saberashraf_2@yahoo.com

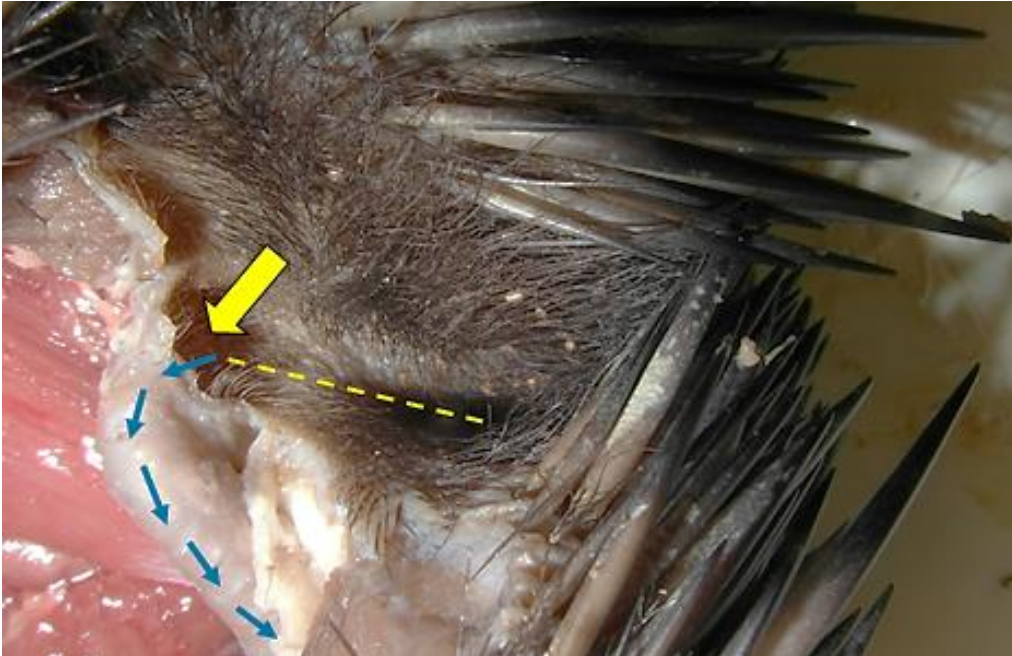


Fig (1): Right external auditory opening of the Echidna. The dashed line indicates the length of the groove at the bottom of which the auditory canal begins (yellow arrow). The blue arrows indicate the direction of the tube to end in the skull.




Fig (2): Right external auditory opening of the Echidna showing: A the embedded funnel-shaped cartilage supporting the auditory groove, the inner side (c). B the cartilage encircling the auditory groove (c). Yellow arrow indicates the auditory groove.

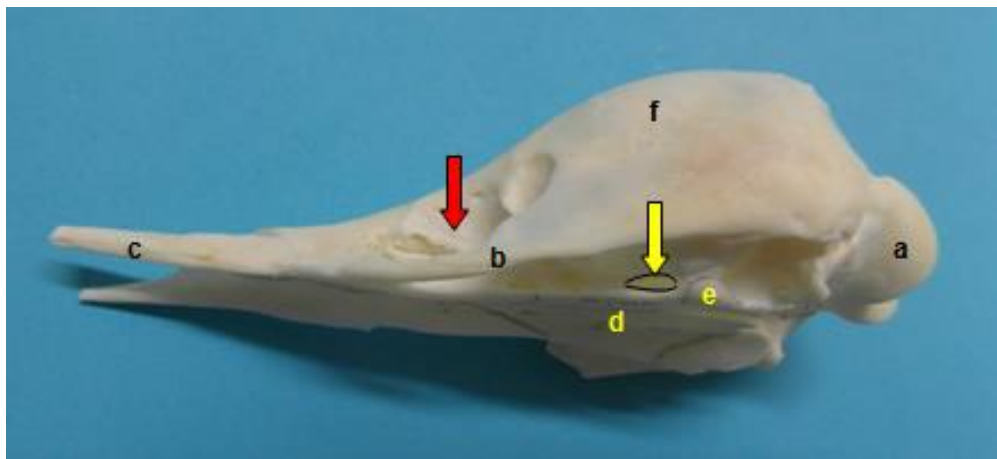


Fig (3): Latero-ventral view of the Echidna skull showing: a occipital condyle, b maxilla, c premaxilla, d palatine bone, e pterygoid bone, f frontal bone. Yellow arrow indicates the auditory opening. Red arrow indicates the orbit. **Note** that there no demarcation of the orbit from the temporal fossa and there is no auditory bulla.

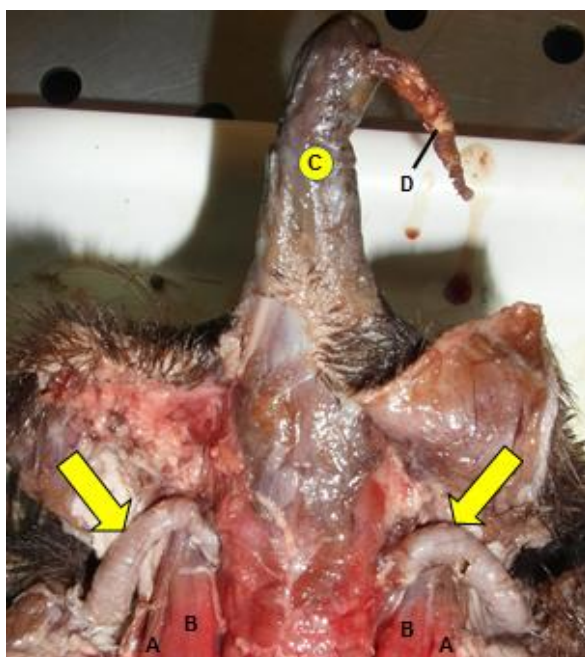


Fig (4): Dissected ventral aspect of the head region of the echidna showing the two auditory canals (yellow arrows) extending from the external opening and ending in the skull. A cleido-mastoid m., B sternomastoid m. C snout (brochen), D tongue (protruded from snout).

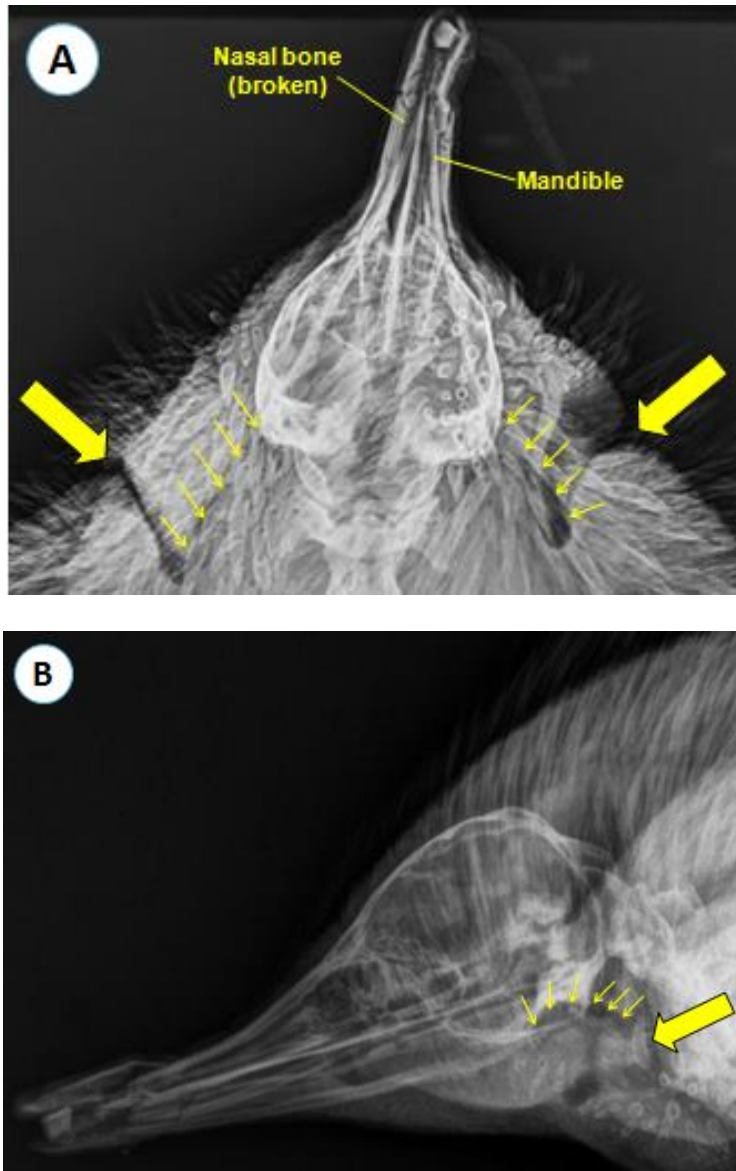


Fig (5): A ventro-dorsal x-ray image of the head region of the echidna, B latero-medial view; showing the entrance to the auditory groove (large arrows), from the bottom of which the external opening of the auditory canal starts, the canal (small arrows) passes cranially and medially to end in the auditory opening at the base of the skull. Notice: the nasal bone is broken because of a car accident.

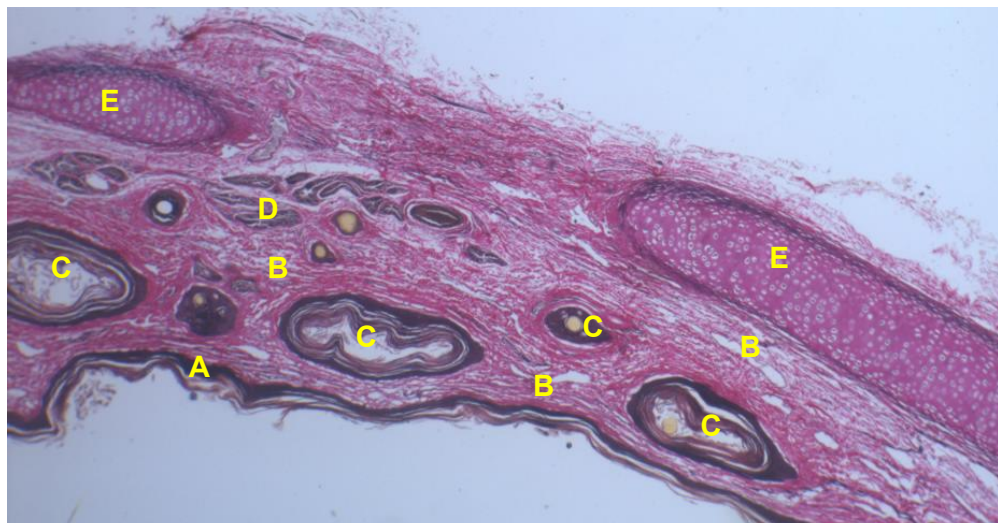

Fig (6): Cross section in the echidna auditory canal showing: (A) epidermal keratinized stratified squamous epithelium, (B) dermal dense connective tissue which contains: (C) hair follicles in cross sections, (D) ceruminous glands, (E) hyaline cartilage (Verhoeff stain, x 10)

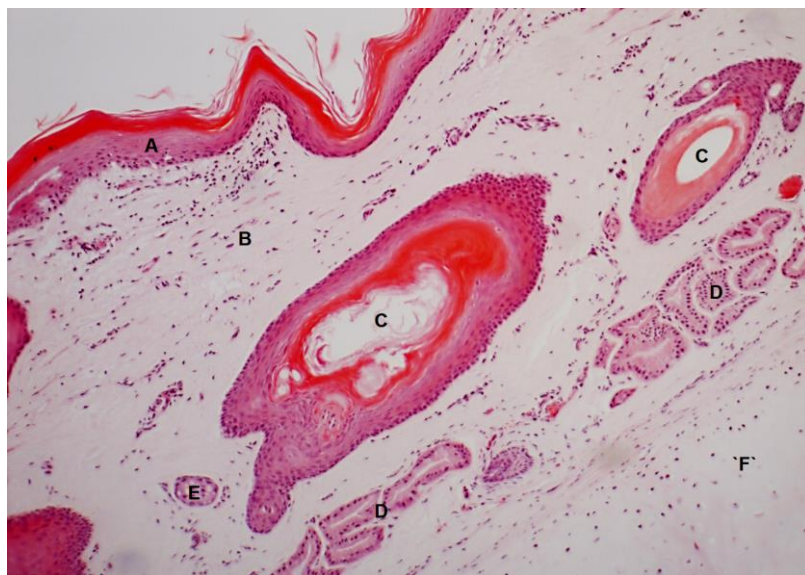


Fig (7): Light micrograph of the echidna auditory canal showing: (A) epidermal keratinized stratified squamous epithelium, (B) dermal dense connective tissue, (C) hair follicles in cross sections, (D) ceruminous glands, (E) sebaceous gland, (F) hyaline cartilage (H&E; x 10). Notice absence of the dermal papillae.

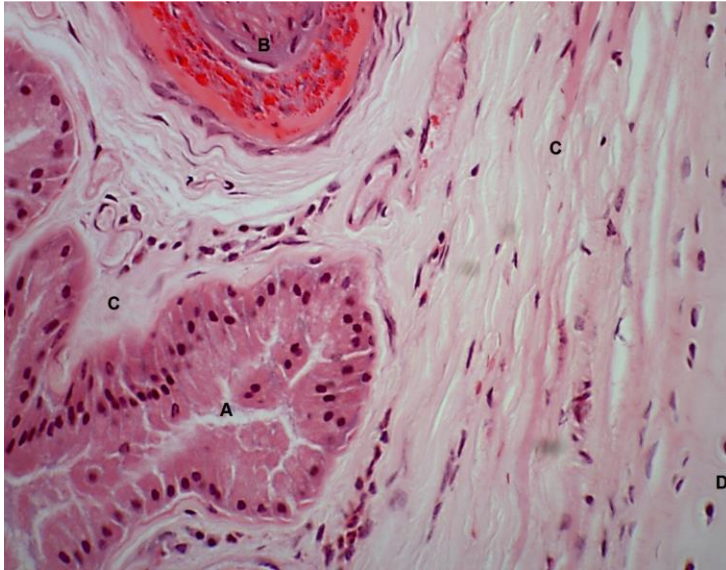


Fig (8): Light micrograph of the echidna auditory canal showing deep dermal layer containing (A) ceruminous glands with apocrine secretion, (B) part of the hair follicle, (C) fibroelastic connective tissue, (D) hyaline cartilage (H&E; x 40)

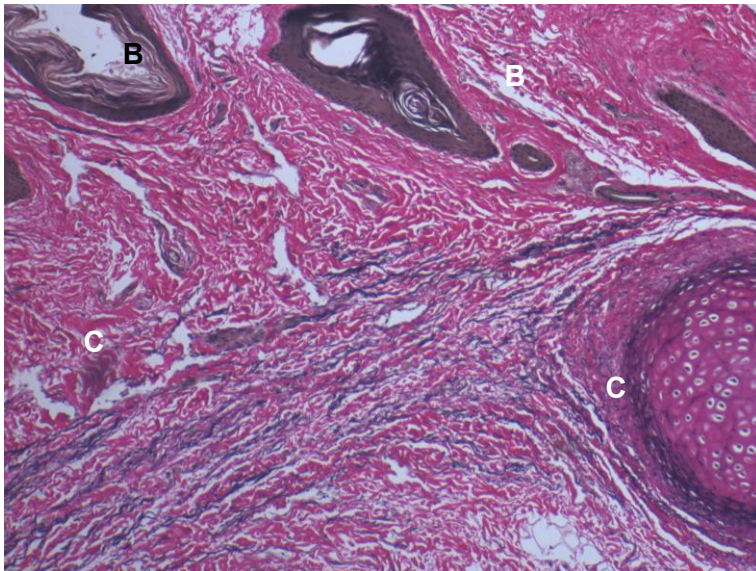


Fig (9): Light micrograph of the echidna auditory canal showing the deep dermal layer, formed of dense connective tissue of collagen (red) and elastic fibers (blue-black) with hair follicles. A hyaline cartilage, B hair follicles C fibroelastic connective tissue (Verhoeff stain; x 40)

Animals of this issue

Echidna (*Tachyglossus aculeatus*)



Kingdom: Animalia & Phylum: Chordata & Class: Mammalia & Order: Monotremata & Family: Tachyglossidae & Genus: *Tachyglossus* & Species: *T. aculeatus*

Echidnas /iˈkɪdnə/, sometimes known as **spiny anteaters**, belong to the family **Tachyglossidae** in the monotreme order of egg-laying mammals. Their diet consists of ants and termites, but they are not closely related to the true anteaters of the Americas. They live in Australia and New Guinea.

Echidnas are small, solitary mammals covered with coarse hair and spines. Superficially, they resemble the anteaters of South America and other spiny mammals such as hedgehogs and porcupines. They have elongated and slender snouts, which function as both, mouth and nose. Like the platypus, they are equipped with electrosensors, but while the platypus has 40,000 electroreceptors on its bill, the long-billed echidna has only 2,000, and the short-billed echidna, which lives in a drier environment, has no more than 400 located at the tip of its snout.

They have very short, strong limbs with large claws, and are powerful diggers. Echidnas have tiny mouths and toothless jaws.

The female lays a single soft-shelled, leathery egg 22 days after mating, and deposits it directly into her pouch. Hatching takes place after 10 days; the young echidna then sucks milk from the pores of the two milk patches (monotremes have no nipples) and remains in the pouch for 45 to 55 days, at which time it starts to develop spines. The mother digs a nursery burrow and deposits the young, returning every five days to suckle it until it is weaned at seven months.

Source: Wikipedia, the free encyclopaedia